International Journal of Computer Assisted Radiology and Surgery
https://doi.org/10.1007/s11548-023-03010-0

SHORT COMMUNICATION

Fully automatic deep learning-based lung parenchyma segmentation and boundary correction in thoracic CT scans

Himanshu Rikhari[1] · Esha Baidya Kayal[1] · Shuvadeep Ganguly[2] · Archana Sasi[2] · Swetambri Sharma[2] · D. S. Dheeksha[4] · Manish Saini[4] · Krithika Rangarajan[3] · Sameer Bakhshi[2] · Devasenathipathy Kandasamy[4] · Amit Mehndiratta[1,5]

Received: 10 January 2023 / Accepted: 25 July 2023
© CARS 2023

Abstract

Purpose The proposed work aims to develop an algorithm to precisely segment the lung parenchyma in thoracic CT scans. To achieve this goal, the proposed technique utilized a combination of deep learning and traditional image processing algorithms. The initial step utilized a trained convolutional neural network (CNN) to generate preliminary lung masks, followed by the proposed post-processing algorithm for lung boundary correction.

Methods First, the proposed method trained an improved 2D U-Net CNN model with *Inception-ResNet-v2* as its backbone. The model was trained on 32 CT scans from two different sources: one from the VESSEL12 grand challenge and the other from AIIMS Delhi. Further, the model's performance was evaluated on a test dataset of 16 CT scans with juxta-pleural nodules obtained from AIIMS Delhi and the LUNA16 challenge. The model's performance was assessed using evaluation metrics such as average volumetric dice coefficient (DSC_{avg}), average IoU score (IoU_{avg}), and average F1 score ($F1_{avg}$). Finally, the proposed post-processing algorithm was implemented to eliminate false positives from the model's prediction and to include juxta-pleural nodules in the final lung masks.

Results The trained model reported a DSC_{avg} of 0.9791 ± 0.008, IoU_{avg} of 0.9624 ± 0.007, and $F1_{avg}$ of 0.9792 ± 0.004 on the test dataset. Applying the post-processing algorithm to the predicted lung masks obtained a DSC_{avg} of 0.9713 ± 0.007, IoU_{avg} of 0.9486 ± 0.007, and $F1_{avg}$ of 0.9701 ± 0.008. The post-processing algorithm successfully included juxta-pleural nodules in the final lung mask.

Conclusions Using a CNN model, the proposed method for lung parenchyma segmentation produced precise segmentation results. Furthermore, the post-processing algorithm addressed false positives and negatives in the model's predictions. Overall, the proposed approach demonstrated promising results for lung parenchyma segmentation. The method has the potential to be valuable in the advancement of computer-aided diagnosis (CAD) systems for automatic nodule detection.

Keywords Computed tomography (CT) · Computer-aided diagnosis (CAD) · Lung parenchyma segmentation · Juxta-pleural nodules · Convolutional neural networks (CNNs)

Introduction

Lung cancer is one of the fatal cancers worldwide. It is the leading cause of cancer deaths worldwide, contributing to almost 25% of all cancer deaths [1]. Each year, lung cancer deaths surpass the combined cancer death statistics for colon, breast, and prostate cancer. The lung nodules are potential representatives of lung cancer [2, 3]. A glossary of

✉ Amit Mehndiratta
amit.mehndiratta@keble.oxon.org

1 Centre for Biomedical Engineering, Indian Institute of Technology Delhi, New Delhi, India

2 All India Institute of Medical Sciences New Delhi, Medical Oncology, Dr. B.R.A. IRCH, New Delhi, India

3 Radiodiagnosis, All India Institute of Medical Sciences New Delhi, Dr. B.R.A. IRCH, New Delhi, India

4 Radiodiagnosis, All India Institute of Medical Sciences New Delhi, New Delhi, India

5 Department of Biomedical Engineering, All India Institute of Medical Sciences New Delhi, New Delhi, India

Published online: 18 August 2023

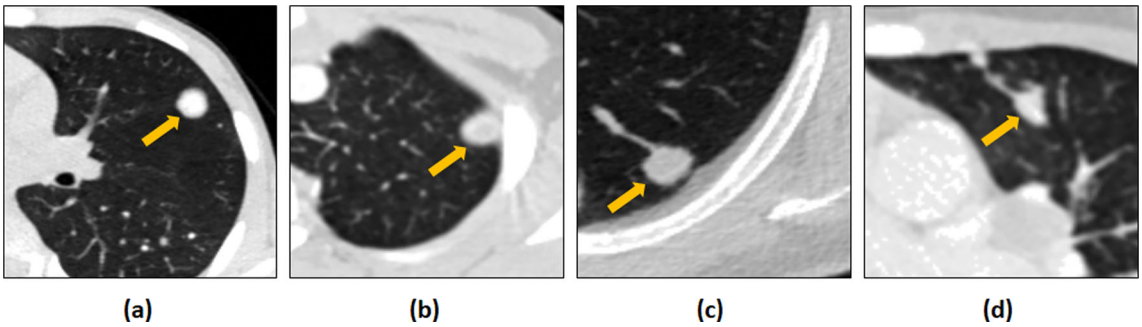

Fig. 1 Lung nodule types: (**a**) Well-circumscribed nodule, (**b**) Juxta-pleural nodule, (**c**) Vascularized nodule, (**d**) Nodule with pleural tail

terms for thoracic imaging [4], published by the Fleischer Society, defined a lung nodule as "any pulmonary or pleural lesion found in a chest radiographs as rounded opacity, well or poorly defined, and measuring up to 30 mm in diameter." Based on their location in the lung and neighboring structures, pulmonary nodules can be grouped into four types: (A) well-circumscribed: the nodule is centrally located in the lung parenchyma with no connections to the vasculature, (B) juxta-pleural: the nodule shares a significant boundary with the pleural surface, (C) vascularized: the nodule is centrally connected to lung while having a significant connection(s) to neighboring vessels, and (D) pleural tail: the nodule is near the pleural surface, connected by thin structure [5]. Figure 1 shows the different types of nodules based on their location in lung parenchyma. Computed tomography (CT) imaging is the worldwide accepted modality for detecting pulmonary nodules. The National Lung Screening Trial (NLST) demonstrated that CT has excellent sensitivity compared to digital chest radiography and can lower lung cancer mortality by 20%. Low-dose computed tomography (LDCT) is accepted as the state-of-the-art protocol for lung nodule detection and helps in early diagnosis for effective treatment planning [6].

Computer-aided diagnosis (CAD) has proven its potential in detecting and characterizing various lesions in lung cancer [7–10]. The primary purpose of such systems is to aid the radiologist throughout the diagnosis and prognosis process and provide a second opinion on the final decision made. Preprocessing, the initial stage of CAD systems, aims to improve the quality of input data for more accurate lung nodule detection. For thoracic CT scans, the preprocessing step includes resampling, rescaling, artifact removal, noise reduction, contrast enhancement, and lung segmentation. Lung segmentation, an essential preprocessing step, separates the lung parenchyma from other anatomical regions visible in the thoracic CT scans, such as the ribs, blood vessels, and the mediastinum. Lung segmentation helps narrow the search space for the subsequent stages of the CAD system, like nodule detection, classification, and segmentation. The primary challenge in automated lung segmentation task is to make the model robust to anatomical variations, the presence of lung pathologies, noise, artifacts, and intensity heterogeneities. Another critical challenge in automated lung segmentation task is to include the juxta-pleural nodules in the lung parenchyma. The juxta-pleural nodules are affixed to the chest wall, and have a similar intensity profile to the chest wall in thoracic CT images; due to this reason, most lung segmentation methods fail to include the juxta-pleural nodules in the segmented lung parenchyma.

Various methods have been proposed in the literature for automated lung parenchyma segmentation, broadly categorized into traditional image processing-based algorithms and deep learning-based algorithms. Traditional image processing approaches such as thresholding [11–15], region-growing [16–19], atlas-based [20, 21], graph cut [22–24], etc., have been widely applied for the lung segmentation task. These methods [11–24] fail to handle high noise and artifacts in the thoracic CT images. In addition, these traditional methods struggle to deal with irregular boundaries, intensity variations, anatomical heterogeneities, and lung pathologies. Most commonly, due to the similar intensity profile of juxta-pleural nodules and chest wall in the CT images [25], these conventional segmentation approaches fail to include juxta-pleural nodules. On the other hand, deep learning methods are known to be immune to noise, artifacts, and intensity variations in the input. Deep learning models could learn complex spatial relationships during training, providing a lung segmentation model that generalizes to different heterogeneities in the thoracic CT images.

Recently, various deep learning-based methods and hybrid approaches have been reported in the literature, which have shown to include the juxta-pleural nodules in the lung parenchyma to improve the overall detection accuracy of CAD systems. Tan J et al. [26] proposed generative adversarial network (GAN)-based deep learning approach for lung segmentation and reported the models' performance on two different datasets with an average and median dice score of 0.985 and 0.986, respectively. However, the authors did not specifically evaluate the model's performance in handling juxta-pleural nodules, a notable limitation despite the high dice score reported. Singadkar G et al. [27] used a dominant

point marching algorithm to include juxta-pleural nodules in the segmented lung parenchyma. A traditional thresholding-based technique obtained the initial lung segmentation. The proposed technique reported an average volumetric overlap of 96.97% on thirty-six subjects selected from the LIDC-IDRI database. However, the traditional thresholding-based technique used by the author may lack generalizability on diverse datasets. An automated gray-level thresholding-based method for lung segmentation and a rolling ball algorithm to include juxta-pleural nodules in the segmented lung parenchyma was proposed by Armato SG et al. [18]. In a database of thirty-eight CT scans, the proposed core lung segmentation approach produced lung regions that missed 17.1% of the lung nodules, while a modified lung segmentation method only excluded 4.9% of the nodules in this database. However, it did not analyze the automated lung segmentation approach on datasets having juxta-pleural nodules.

A fully automated algorithm was proposed utilizing active shape modeling [28] that can include juxta-pleural nodules in the lung mask. The suggested approach reported a mean dice score of 90.3% when applied to seven CT slices containing juxta-pleural nodules. A novel algorithm by Chung H et al. [29] for lung segmentation that also claimed to detect juxta-pleural nodules used Chan-Vase (CV) to extract lung contour and used the Bayesian approach to include juxta-pleural nodules in the lung mask. Additionally, concave point detection and circle or ellipse Hough transform techniques were used to eliminate false positives. The suggested method reported a dice coefficient of 0.97 on 314 CT slices with juxta-pleural nodules. The techniques proposed in [30] used nonlinear anisotropic filtering and fuzzy-c means clustering method for lung segmentation, and later an adaptive curvature threshold technique was used to include juxta-pleural nodules and pulmonary vessels in the lung mask. This technique reported a $95.81 \pm 0.89\%$ volume overlap ratio on twenty CT scans with sixty-five juxta-pleural nodules. The algorithm employed in [31] used a combination of multiple image segmentation strategies, including optimized thresholding, region-growing, seed-based random walk, and curvature-based correction for lung segmentation. The methodology reported an overlap ratio of 98.4% on twenty-three thoracic CT scans. However, the algorithm's performance in handling juxta-pleural nodules was not explicitly stated. A convolutional neural network (CNN) based method [32] used the clustering algorithm to generate annotated data to train the single-layer CNN. The method reported an overlap of 0.96 when validated on 201 subjects with heterogeneous lung diseases and CT scanners. The work presented in [33] highlighted the importance of diverse datasets for training the CNN. The proposed work trained generic networks such as U-Net, ResU-Net, and Deeplab v3 + on diverse thoracic CT scans that contained a range of lung pathologies, image acquisition protocols, and patient demographics. The research concludes that boosting the training data quality and diversity is essential for improving automatic lung segmentation in routine medical imaging.

The current study presents an efficient and robust approach for lung parenchyma segmentation, specifically addressing the inclusion of juxta-pleural nodules. The methodology combines a deep learning-based U-Net model with traditional image processing algorithms as a post-processing step. The efficacy of the proposed algorithm is assessed on a test dataset of sixteen CT scans.

The novel contributions and highlights of the proposed work are: Firstly, a fully automatic lung segmentation algorithm is developed by leveraging the strengths of deep learning and traditional image processing techniques. The CNN model effectively addresses noise, artifacts, and poor contrast in CT scans, significantly improving accuracy and generalizability. Additionally, a post-processing algorithm, incorporating the convex hull and region-based properties like the center of mass and area, is employed to accurately include juxta-pleural nodules within the segmented lung mask while removing irrelevant predictions. Lastly, the comprehensive pipeline can be directly integrated into CAD systems workflows, enhancing the overall accuracy of lung nodule analysis in thoracic CT scans.

Methods

This section outlines the step-by-step process followed in the proposed technique. Figure 2 shows the schematic of the proposed workflow. The following subsections detail the datasets used for training and testing, the architecture of the lung segmentation model, the experimental setup, and the steps involved in the post-processing technique.

Datasets

Training dataset

The proposed automatic lung segmentation technique utilized 32 CT scans from two different sources: first, the publicly available VESSEL12 grand challenge dataset [34] and second, retrospective dataset acquired from AIIMS Delhi with Institute Ethical Board approval. The VESSEL12 dataset is a collection of 20 isotropic CT scans from various sources and protocols with voxel spacing between 0.59 and 0.89 mm, slice spacing of approximately 1 mm; further, emphysema, nodules, or pulmonary embolism are among the abnormalities present in around half of the scans. The voxel type for the CT scans and lung masks had SHORT (16-bit signed) and UCHAR (8-bit unsigned), respectively. The dataset obtained from AIIMS Delhi consists of 12 patients' 3D thoracic CT scans with juxta-pleural nodules. The dataset was acquired using multislice scanners from GE Medical

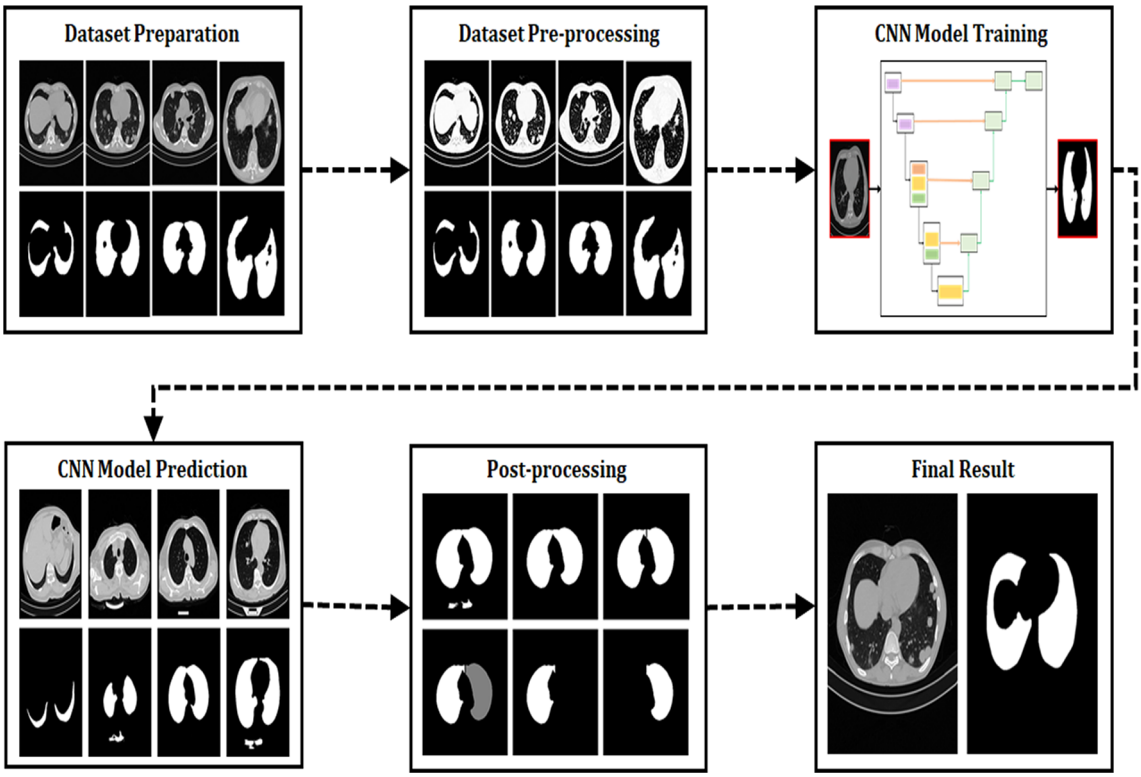

Fig. 2 Schematic representation of the proposed approach for lung parenchyma segmentation

Systems, Siemens healthineers, and Philips Medical Systems. The technical parameters for the scans included an X-ray tube voltage of 100–120 kV based on the patient's age, a matrix size of 512 × 512, a voxel size of 0.5 − 0.7 × 0.5 − 1 × 1 − 1.5 mm^3, and a reconstruction interval of 1.0 − 1.5 mm. The CT scan voxels had 16-bit (int16) resolution on a grayscale in Hounsfield (HU) unit. The scanner determined the milliamperes (mA) used for the scan using automatic tube current modulation.

The VESSEL12 dataset had more than 7000 lung CT images provided with lung masks having the pixel values 0 and 1 for non-lung and the lung parenchyma, respectively, and the retrospective data of 12 patients with juxta-pleural nodules obtained from AIIMS Delhi, each CT scan had 120 to 500 slices, and 3329 CT slices in total. The ground truth labeling for the AIIMS Delhi dataset was done using a traditional thresholding technique, and then a four-year experienced radiologist in pulmonary imaging corrected the lung masks to precisely include the juxta-pleural nodules, in the next step; the final lung masks were verified by an expert radiologist with more than fifteen-year experience in the same field. MRIcron software was used to correct the lung masks obtained from the thresholding operation. Figure 3 shows image examples with corresponding labels used to train the CNN model.

Test dataset

The test dataset utilized a total of 16 CT scans with juxta-pleural nodules, ten of which were obtained from the publicly available LUNA16 challenge [35] and six from the dataset acquired in-house at AIIMS Delhi. Each CT scan had 111 to 542 slices. The LUNA16 challenge was dedicated to develop algorithms for lung nodule detection and segmentation; it comprises over 1000 scans with annotations for the nodules in the CT scans. The current work selected 10 CT scans with juxta-pleural nodules from the LUNA16 dataset to make the test dataset diverse. The ground truths for the test dataset were generated using the same strategy utilized in preparing the ground truth labels for the training dataset.

Lung segmentation model

The proposed work utilized TensorFlow platform-based 2D U-Net architecture with *Inception-ResNet-v2* as the backbone (configurational element of the encoder) [36, 37]. The decoder stage was designed based on the configuration of the backbone. Figure 4A provides a schematic representation of the CNN architecture, while Fig. 4B depicts the detailed structures of the encoder and decoder components.

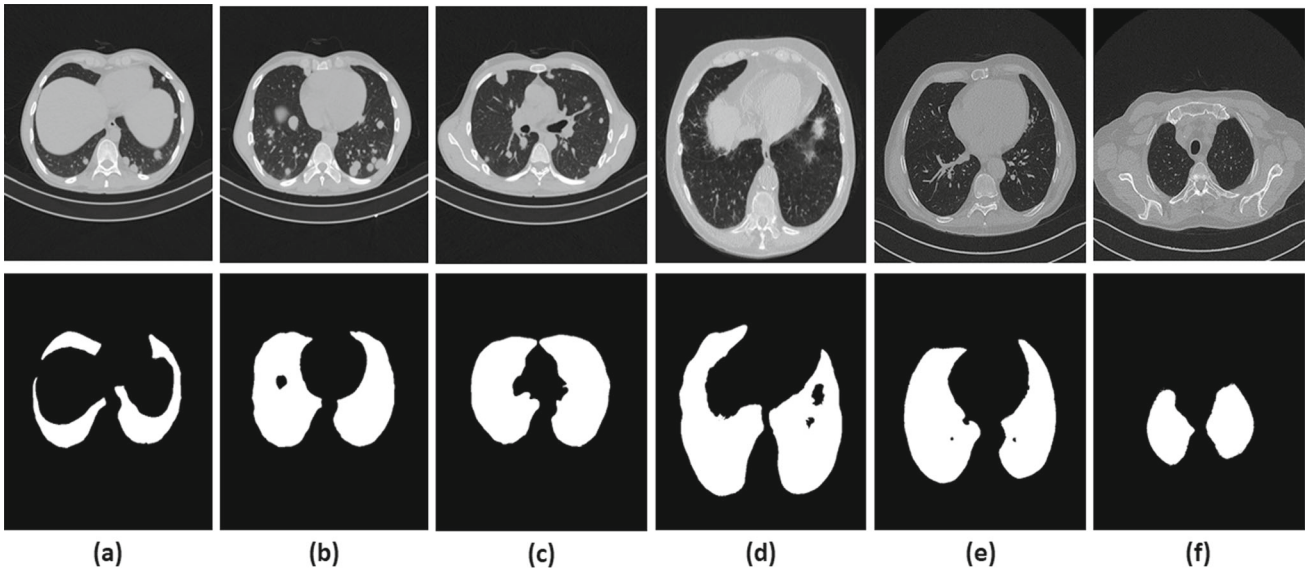

Fig. 3 Sample images from the training dataset. (**a**), (**b**), (**c**) with corresponding manually labeled ground truth are sample images from AIIMS Delhi dataset, and (**d**), (**e**), (**f**) with corresponding ground truth are sample images from the VESSEL12 dataset

The U-Net [38] is an extension of a fully convolutional encoder-decoder network and is widely used for its exceptional performance in medical image segmentation tasks. The deep structure of the Inception-ResNet-v2 as encoder enables the learning of intricate features while maintaining computational efficiency, despite its depth. Additionally, Inception-ResNet-v2 combines the advantages of both the Inception and ResNet architectures. The inception modules apply 1×1, 3×3, and 5×5 convolutional kernels in parallel, which could capture complex spatial features at different scales. The residual connections between convolutional blocks allow the network to learn residual mappings and enable effective gradient flow. By integrating Inception-ResNet-v2 with U-Net's skip connections and decoder path, the model can effectively capture both local and global context, leading to more precise and detailed lung parenchyma segmentation outcomes.

Experiment details

The current work employed slice-level training for the segmentation model to manage memory requirements. The 3D CT scan dataset obtained from AIIMS Delhi was first resampled to have an isotropic voxel size of $0.65 \times 0.65 \times 1\ \text{mm}^3$; after that, the sample-wise image intensities were normalized to 0–1 range. The dataset obtained from VESSEL12 was isotropic; hence, only intensity normalization was performed to 0–1 range. During training and testing, the CT images were rescaled to a resolution of 256×256.

Out of 32 CT scans utilized in the study, six CT scans (three from each dataset) were allocated to the validation dataset, ensuring an unbiased evaluation of the trained models' performance. After a patient-wise split, the training dataset comprised over 8000 images, while the validation dataset comprised more than 2000 images. To enhance the training process and mitigate overfitting, a data augmentation technique was implemented with a focused augmentation of CT slices having juxta-pleural nodules. This technique effectively increased the diversity and quantity of the training data by applying various transformations such as rotation [− 30, 30 degrees], cropping (up to 30%), shearing [− 30, 30 degrees], scaling (using gamma transform in the range of 0.5 to 2.5), and vertical-horizontal flipping. 21,844 images were found in the training dataset after the application data augmentation technique.

The CNN model used the segmentation models [36] library to import the model architecture described in the methods section; the google colab pro environment was used to train the CNN model. Multiple evaluation metrics, including the Dice score, F1 score, and Intersection over Union (IoU) score, were used to assess the performance of the segmentation model during training. Further, the average volumetric dice coefficient (DSC_{avg}), average IoU score (IoU_{avg}), and average F1 score ($F1_{avg}$) were used to assess the performance of the trained deep learning model on the test dataset; the performance of the trained model was initially evaluated on individual CT scans in test dataset; then, the scores were averaged to determine the mean value of the evaluation metrics. Additionally, the performance of the proposed post-processing algorithm was separately evaluated on the CT slices with juxta-pleural nodules obtained from the test dataset.

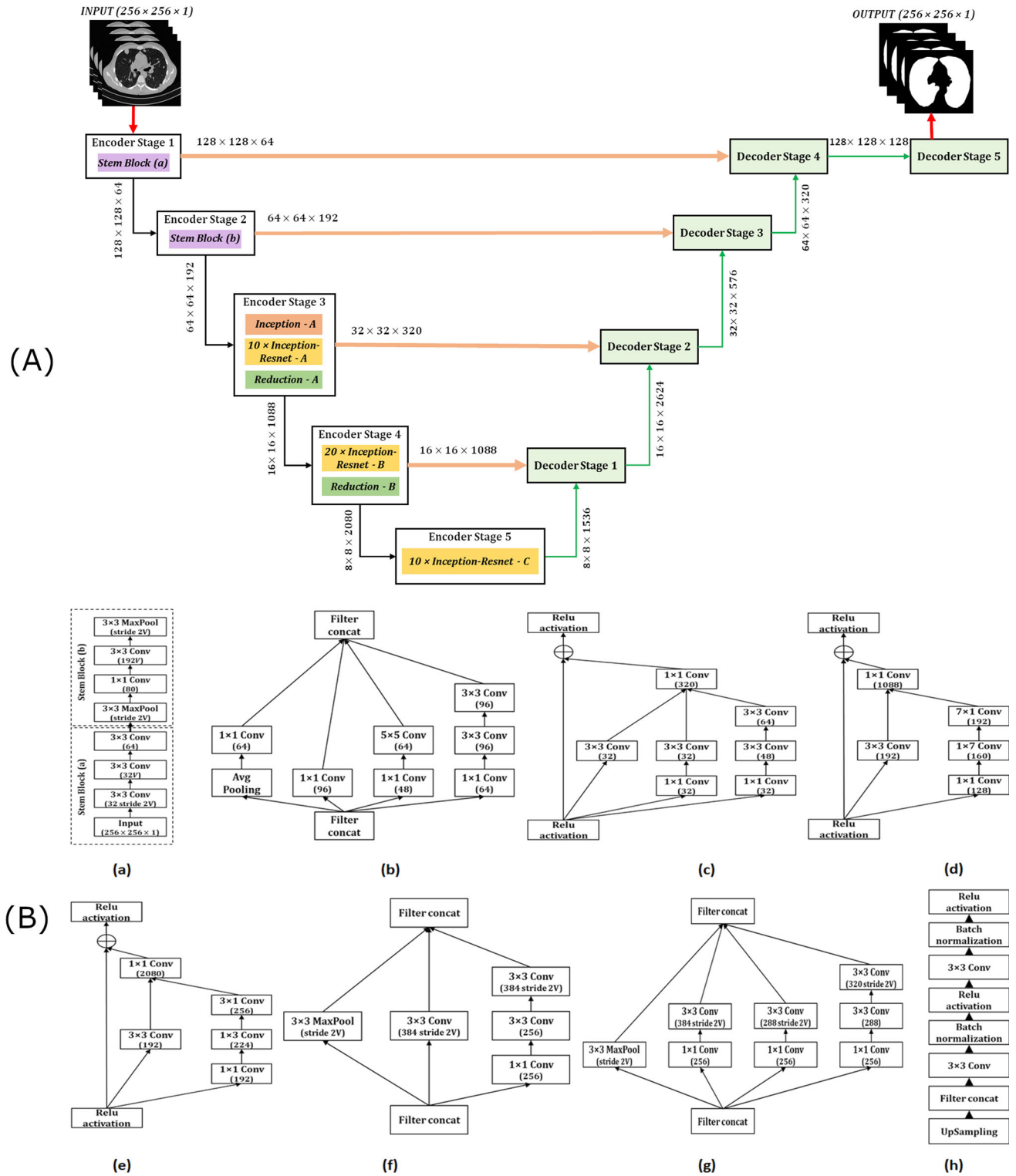

Fig. 4 (**A**) Schematic representation of the U-Net architecture with Inception-ResNet-v2 backbone (adapted from [36]) for lung parenchyma segmentation. (**B**) Detailed structures of encoder (adapted from [37]) and decoder components in the U-Net architecture. (a) the Stem Block, (b) the Inception-A module, (c) the Inception-ResNet-A module, (d) the Inception-ResNet-B module, (e) the Inception-ResNet-C module, (f) the Reduction-A module, (g) the Reduction-B module and, (h) the Decoder Stage module

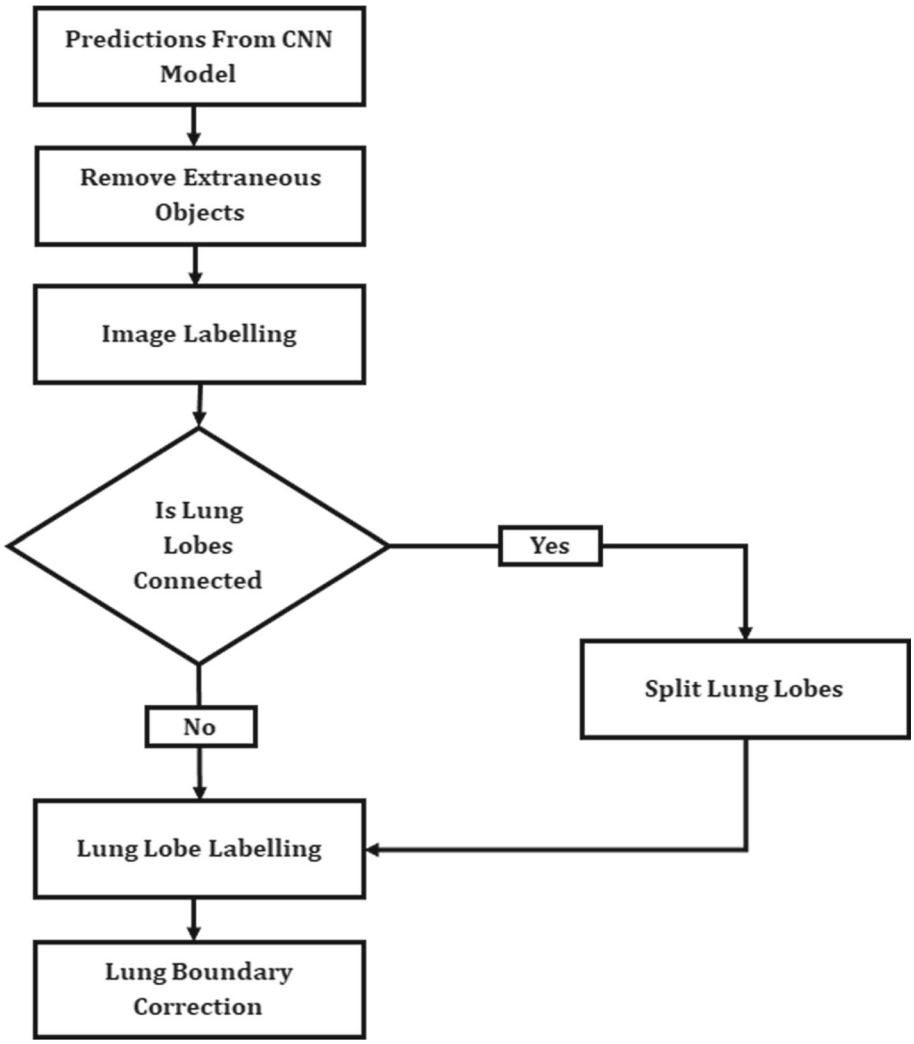

Fig. 5 Flowchart of the steps involved in the post-processing algorithm

The deep learning model utilized in this study was trained using specific hyperparameter settings. These settings included an input image size of 256 × 256 pixels, a batch size of 32, and an initial learning rate of 0.001. The model was trained for a total of 50 epochs using the ADAM optimizer. To optimize the training process, a combination of dice loss and binary cross-entropy was employed as the loss function. Additionally, a learning rate scheduler was implemented with a decreasing learning rate by a factor of 0.1 after five epochs of validation patience.

Post-processing and boundary correction

The trained model's predictions included extraneous predictions (False Positives) and failed to predict the juxta-pleural regions (False Negatives) accurately in some cases. As a result, an algorithm utilizing conventional morphological techniques and connected component analysis was developed to rectify these inaccuracies in the model's predictions. Figure 5 shows the flowchart of the developed algorithm; the steps involved in the algorithm are described below.

Step 1: In this step, lung masks were obtained for the test dataset utilizing the trained CNN model. Further, the predicted lung masks were checked for including juxta-pleural nodules and false positives.

Step 2: The false positive structures were eliminated utilizing region-based properties. Isolated and extraneous structures in the predicted masks contributing up to ten percent of the overall image area were removed (Fig. 6).

Step 3: The convex hull algorithm was utilized to include juxta-pleural nodules into the lung mask. The algorithm was applied individually on to the left and the right lung. However, a few slices in most thoracic CT scans have a minor anterior overlap; hence, the lung lobes were separated with a three-pixel-thick, zero-intensity perpendicular line along the width of the image, as shown in Fig. 7.

Step 4: The connected component analysis was used to separate the lung lobes into two separate objects, as shown in Fig. 8.

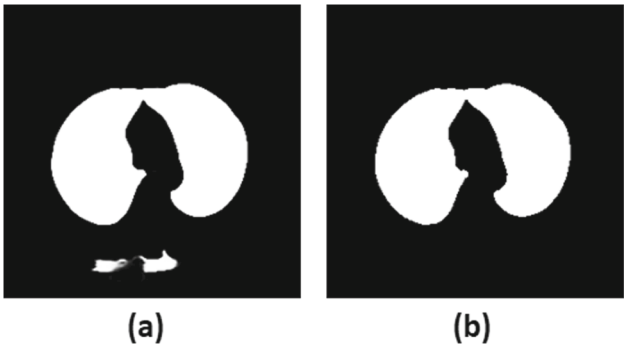

Fig. 6 Removal of false positives from the model prediction. (**a**) the predicted image with extraneous structures, and (**b**) the corrected image

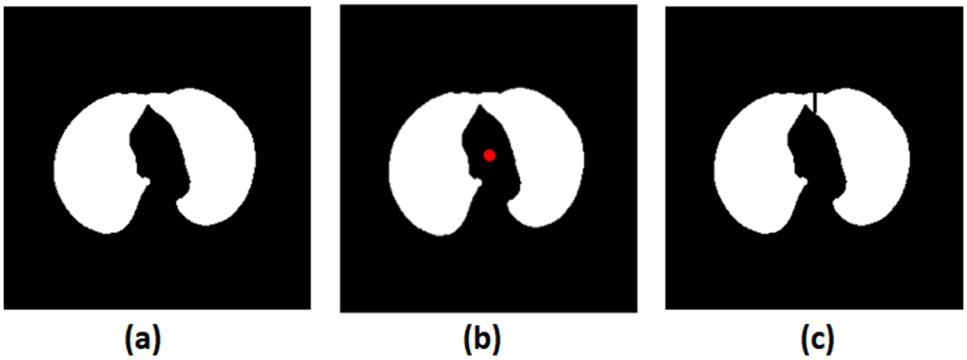

Fig. 7 Separating lung lobes. (**a**) the connected lung lobes, (**b**) the centroid point of the image, and (**c**) the separated lung lobes



Fig. 8 Separated right and left lung lobes. (**a**) labeled image, (**b**) the right lung, and (**c**) the left lung



Fig. 9 Sequence of steps to include juxta-pleural nodules in the lung parenchyma

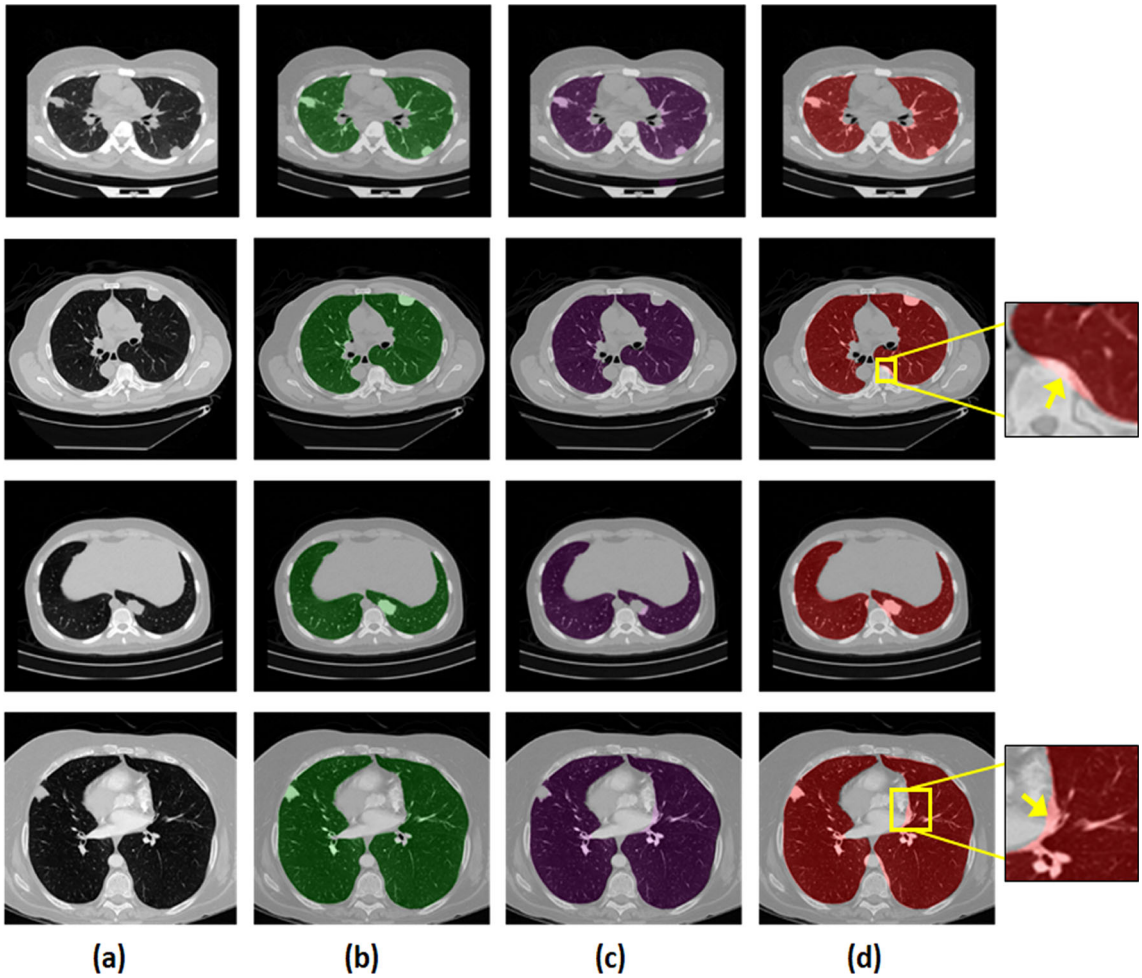

Fig. 10 Representative results of lung masks through the proposed technique on the test dataset. Column (**a**) shows CT slices with juxta-pleural nodules, column (**b**) shows the ground truth lung mask overlay, column (**c**) shows the model predicted lung mask overlay, and column (**d**) shows the post-processed lung mask overlay, on the CT slices. Oversegmentation of lung boundaries near mediastinum and vertebral body shown in the magnified image from column (**d**)

Step 5: The convex hull algorithm, along with binary image operations, were employed in the final step. The convex hull algorithm removes image concavities and has minimal impact on the naturally convex lung lobes on the outer boundary. It effectively addresses the concave tendencies of nodules on the boundary. However, it fills the initially concave inner lung boundaries. To remove the superfluous part on the inner section of the lungs, binary subtraction followed by the largest component removal was carried out. The remaining region was added to the originally predicted lung mask. Finally, the separated lungs were joined to obtain a boundary-corrected lung parenchyma image. Figure 9 depicts the series of actions taken to obtain the final result.

Results and discussions

The proposed deep learning model obtained a dice coefficient of 0.9684, an IoU score of 0.9569, and an F1 score of 0.9720 on the validation dataset. Furthermore, the trained model reported a DSC_{avg} of 0.9791 ± 0.008, IoU_{avg} of 0.9624 ± 0.007, and $F1_{avg}$ of 0.9792 ± 0.004 on the test dataset assembled from 16 different CT scans.

The predictions made by the trained deep learning model demonstrated high volumetric overlap scores and included juxta-pleural nodules in the segmented lung mask. However, on careful examination, it was observed that some juxta-pleural nodules were not included in the predicted lung mask. In addition, some additional structures were predicted as false positives, which could hamper the performance of CAD systems in later stages. Hence, the post-processing algorithm was developed to resolve the shortcomings of the model predictions. Figure 10c displays a few sample predictions overlaid on corresponding CT slices. Applying the proposed post-processing algorithm to the predicted lung mask from the test dataset obtained a DSC_{avg} of 0.9713 ± 0.007, IoU_{avg} of 0.9486 ± 0.007, and $F1_{avg}$ of 0.9701 ± 0.008. Table 1

Table 1 Results of the proposed technique on the test dataset

Subjects	Number of CT slices	Results from CNN model prediction			Results after boundary correction		
		DSC_{avg}	IoU_{avg}	$F1_{avg}$	DSC_{avg}	IoU_{avg}	$F1_{avg}$
1	220	0.9708	0.9407	0.9694	0.9642	0.9324	0.9642
2	264	0.9796	0.9583	0.9787	0.9742	0.9456	0.9724
3	536	0.9807	0.9606	0.9800	0.9715	0.9482	0.9714
4	337	0.9864	0.9719	0.9769	0.9794	0.9564	0.9528
5	542	0.9613	0.9623	0.9680	0.9531	0.9479	0.9779
6	300	0.9865	0.9726	0.9861	0.9781	0.9501	0.9582
7	300	0.9851	0.9716	0.9856	0.9803	0.9586	0.9803
8	343	0.9836	0.9662	0.9828	0.9701	0.9558	0.9698
9	320	0.9800	0.9601	0.9787	0.9720	0.9453	0.9799
10	117	0.9827	0.9659	0.9827	0.9715	0.9492	0.9715
11	371	0.9840	0.9665	0.9803	0.9784	0.9558	0.9783
12	111	0.9830	0.9637	0.9815	0.9741	0.9538	0.9740
13	114	0.9791	0.9558	0.9774	0.9702	0.9454	0.9688
14	375	0.9804	0.9615	0.9804	0.9682	0.9468	0.9661
15	127	0.9828	0.9625	0.9807	0.9756	0.9502	0.9756
16	525	0.9593	0.9579	0.9784	0.9604	0.9368	0.9604
Mean ± Std. Dev		0.9791 ± 0.0082	0.9624 ± 0.0077	0.9792 ± 0.0049	0.9713 ± 0.0073	0.9486 ± 0.0069	0.9701 ± 0.0080

presents the experimental results on the test dataset with 16 CT scans. Furthermore, a separate experiment was conducted utilizing 172 CT slices with juxta-pleural nodules and the corresponding model predicted lung masks. Applying the post-processing technique to the predicted lung masks obtained an average slice-wise dice coefficient of 0.9755 ± 0.011 compared to the dice coefficient of 0.9785 ± 0.009 obtained from the model's prediction.

Figure 10d demonstrates the boundary-corrected lung masks utilizing the proposed post-processing algorithm, which successfully handled the purpose of eliminating false positives and including juxta-pleural nodules from the predicted lung mask. However, despite this successful inclusion, the volumetric dice score did not show any significant improvement compared to the predictions made by the deep learning model alone. This suggests that while the algorithm effectively incorporated the juxta-pleural nodules, it also introduced some over-segmentation (false positive) regions near the lung boundaries (limited to regions close to the mediastinum and vertebral body), as shown in Fig. 10d.

For future research, several potential areas can be explored. Firstly, it is crucial to incorporate a wider range of CT scans in training the CNN model. This approach can further enhance and generalize the model's performance, leading to a more comprehensive lung segmentation. Moreover, addressing the issue of over-segmentation near the lung borders necessitates optimizing the post-processing algorithm while maintaining the overall segmentation effectiveness. Finally, an important aspect that was not evaluated in this research is the interrater and intrarater variability. These measures assess the level of agreement or disagreement among different raters or evaluators and should be considered in future studies.

Conclusion

The proposed method utilized a generic U-Net model with *Inception-ResNet-v2* as the backbone for lung segmentation. The proposed technique utilized diverse CT scans dataset for the training, validation, and testing of the CNN model. A patient-wise data split was performed to ensure unbiased training of the CNN model. Furthermore, with a specific focus on including juxta-pleural nodules in the lung mask, more than thirty percent of the training data incorporated the lung CT slices having juxta-pleural nodules. Data augmentation strategies were used to improve the models' performance and generalizability. The trained CNN models' performance was assessed on a test dataset of sixteen CT scans that produced a DSC_{avg} of 0.9791 ± 0.008, IoU_{avg} of 0.9624 ± 0.007, and $F1_{avg}$ of 0.9792 ± 0.004.

Despite the effectiveness of the model's predictions, there were instances where juxta-pleural nodules were not adequately included in the final lung mask. To address this

limitation, the proposed post-processing algorithm was used to incorporate these nodules into the lung mask and produced a DSC_{avg} of 0.9713 ± 0.007, IoU_{avg} of 0.9486 ± 0.007, and $F1_{avg}$ of 0.9701 ± 0.008 on the test dataset. However, it was observed that this approach led to some over-segmentation near the lung boundaries. Overall, the proposed method presents an efficient and robust solution for lung parenchyma segmentation that effectively includes juxta-pleural nodules. The integration of this technique into CAD systems can further improve the accuracy of lung nodule analysis in thoracic CT imaging workflow, facilitating early diagnosis and treatment planning for lung cancer patients.

Funding This research received external funding from Indian Council of Medical Research (ICMR), New Delhi, India (AI-Adhoc/06/2022-AI Cell).

Declarations

Competing interests The authors declare that they have no competing interests.

Ethical approval Protocol for this retrospective study was approved by the Institute Ethics Committee of All India Institute of Medical Sciences, New Delhi, India.

References

1. Lung Cancer Statistics | How Common is Lung Cancer? https://www.cancer.org/cancer/lung-cancer/about/key-statistics.html. Accessed 26 Sep 2022
2. Liu Y, Wang H, Li Q, McGettigan MJ, Balagurunathan Y, Garcia AL, Thompson ZJ, Heine JJ, Ye Z, Gillies RJ, Schabath MB (2017) Radiologic Features of Small Pulmonary Nodules and Lung Cancer Risk in the National Lung Screening Trial: A Nested Case-Control Study. https://doi.org/10.1148/radiol2017161458 286:298–306.
3. Larici AR, Farchione A, Franchi P, Ciliberto M, Cicchetti G, Calandriello L, del Ciello A, Bonomo L (2017) Lung nodules: size still matters. Eur Respir Rev. https://doi.org/10.1183/16000617.0025-2017
4. Hansell DM, Bankier AA, MacMahon H, McLoud TC, Müller NL, Remy J (2008) Fleischner Society: Glossary of terms for thoracic imaging. Radiology 246:697–722
5. Kostis WJ, Reeves AP, Yankelevitz DF, Henschke CI (2003) Three-Dimensional Segmentation and Growth-Rate Estimation of Small Pulmonary Nodules in Helical CT Images. IEEE Trans Med Imaging 22:1259–1274
6. Team TNLSTR (2013) Results of Initial Low-Dose Computed Tomographic Screening for Lung Cancer. N Engl J Med 368:1980
7. Halder A, Dey D, Sadhu AK (2020) Lung Nodule Detection from Feature Engineering to Deep Learning in Thoracic CT Images: a Comprehensive Review. J Digit Imaging 33:655–677
8. da Silva Sousa JRF, Silva AC, de Paiva AC, Nunes RA (2010) Methodology for automatic detection of lung nodules in computerized tomography images. Comput Methods Programs Biomed 98:1–14
9. Nishio M, Sugiyama O, Yakami M, Ueno S, Kubo T, Kuroda T, Togashi K (2018) Computer-aided diagnosis of lung nodule classification between benign nodule, primary lung cancer, and metastatic lung cancer at different image size using deep convolutional neural network with transfer learning. PLoS ONE 13:e0200721
10. Mahersia H, Zaroug M, Gabralla L (2015) Lung Cancer Detection on CT Scan Images: A Review on the Analysis Techniques. Int J Adv Res Artif Intell. https://doi.org/10.14569/IJARAI.2015.040406
11. Hu S, Hoffman EA, Reinhardt JM (2001) Automatic lung segmentation for accurate quantitation of volumetric X-ray CT images. IEEE Trans Med Imaging 20:490–498
12. Leader JK, Zheng B, Rogers RM, Sciurba FC, Perez A, Chapman BE, Patel S, Fuhrman CR, Gur D (2003) Automated lung segmentation in X-ray computed tomography: development and evaluation of a heuristic threshold-based scheme. Acad Radiol 10:1224–1236
13. Nurfauzi R, Nugroho HA, Ardiyanto I (2017) Lung detection using Adaptive Border correction. Proceeding - 2017 3rd Int Conf Sci Technol ICST 2017 57–60.
14. Li XY, Xu F, Hu X, Peng SH, Do NH, Zhao JM (2017) Self-adapting threshold of pulmonary parenchyma. Proc - 2016 9th Int Congr Image Signal Process Biomed Eng Informatics. CISP-BMEI 2016:1429–1434
15. Wei Y, Shen G, Li JJ (2013) A fully automatic method for lung parenchyma segmentation and repairing. J Digit Imaging 26:483–495
16. El-Regaily SA, Salem MAM, Aziz MHA, Roushdy MI (2017) Lung nodule segmentation and detection in computed tomography. 2017 IEEE 8th Int Conf Intell Comput Inf Syst ICICIS 2017 2018-January:72–78.
17. Sun S, Li W, Kang Y (2016) Lung nodule detection based on GA and SVM. Proc - 2015 8th Int Conf Biomed Eng Informatics. BMEI 2015:96–100
18. Armato SG, Sensakovic WF (2004) Automated lung segmentation for thoracic CT impact on computer-aided diagnosis. Acad Radiol 11:1011–1021
19. Zhang W, Wang X, Li X, Chen J (2018) 3D skeletonization feature based computer-aided detection system for pulmonary nodules in CT datasets. Comput Biol Med 92:64–72
20. Li Z, Hoffman EA, Reinhardt JM (2006) Atlas-driven lung lobe segmentation in volumetric X-ray CT images. IEEE Trans Med Imaging 25:1–16
21. Zhang L, Reinhardt JM 3D Pulmonary CT Image Registration with a Standard Lung Atlas. Proc. SPIE 3978, Medical Imaging 2000: Physiology and Function from Multidimensional Images. doi: https://doi.org/10.1117/12383441
22. Chen X, Udupa JK, Bagci U, Zhuge Y, Yao J (2012) Medical image segmentation by combining graph cuts and oriented active appearance models. IEEE Trans Image Process 21:2035–2046
23. Wels M, Carneiro G, Aplas A, Huber M, Hornegger J, Comaniciu D (2008) A discriminative model-constrained graph cuts approach to fully automated pediatric brain tumor segmentation in 3-D MRI. Lect Notes Comput Sci (including Subser Lect Notes Artif Intell Lect Notes Bioinformatics) 5241 LNCS:67–75.
24. Tsai YP, Ko CH, Hung YP, Shih ZC (2007) Background removal of multiview images by learning shape priors. IEEE Trans Image Process 16:2607–2616
25. Benzakoun J, Bommart S, Coste J, Chassagnon G, Lederlin M, Boussouar S, Revel MP (2016) Computer-aided diagnosis (CAD) of subsolid nodules: Evaluation of a commercial CAD system. Eur J Radiol 85:1728–1734
26. Tan J, Jing L, Huo Y, Li L, Akin O, Tian Y (2021) LGAN: Lung segmentation in CT scans using generative adversarial network. Comput Med Imaging Graph 87:1–24
27. Singadkar G, Mahajan A, Thakur M, Talbar S (2021) Automatic lung segmentation for the inclusion of juxtapleural nodules and pulmonary vessels using curvature based border correction. J King Saud Univ - Comput Inf Sci 33:975–987

28. Shariaty F, Orooji M, Mousavi M, Baranov M, Velichko E (2020) Automatic lung segmentation in computed tomography images using active shape model. Proc 2020 IEEE Int Conf Electr Eng Photonics. EExPolytech 2020:156–159
29. Chung H, Ko H, Jeon SJ, Yoon KH, Lee J (2018) Automatic Lung Segmentation with Juxta-Pleural Nodule Identification Using Active Contour Model and Bayesian Approach. IEEE J Transl Eng Heal Med. https://doi.org/10.1109/JTEHM.2018.2837901
30. Zhou S, Cheng Y, Tamura S (2014) Automated lung segmentation and smoothing techniques for inclusion of juxtapleural nodules and pulmonary vessels on chest CT images. Biomed Signal Process Control 13:62–70
31. Shi Z, Ma J, Zhao M, Liu Y, Feng Y, Zhang M, He L, Suzuki K (2016) Many Is Better Than One: An Integration of Multiple Simple Strategies for Accurate Lung Segmentation in CT Images. Biomed Res Int. https://doi.org/10.1155/2016/1480423
32. Xu M, Qi S, Yue Y, Teng Y, Xu L, Yao Y, Qian W (2019) Segmentation of lung parenchyma in CT images using CNN trained with the clustering algorithm generated dataset 08 Information and Computing Sciences 0801 Artificial Intelligence and Image Processing Robert Koprowski. Biomed Eng Online 18:1–21
33. Hofmanninger J, Prayer F, Pan J, Röhrich S, Prosch H, Langs G (2020) Automatic lung segmentation in routine imaging is primarily a data diversity problem, not a methodology problem. Eur Radiol Exp. https://doi.org/10.1186/s41747-020-00173-2
34. Home - Grand Challenge. https://vessel12.grand-challenge.org/. Accessed 27 Sep 2022
35. Download - Grand Challenge. https://luna16.grand-challenge.org/Download/. Accessed 27 Sep 2021
36. qubvel/segmentation_models: Segmentation models with pretrained backbones. Keras and TensorFlow Keras. https://github.com/qubvel/segmentation_models. Accessed 7 Jan 2023
37. Szegedy C, Ioffe S, Vanhoucke V, Alemi AA (2017) Inception-v4, inception-ResNet and the impact of residual connections on learning. 31st AAAI Conf Artif Intell AAAI 2017 4278–4284.
38. Ronneberger O, Fischer P, Brox T (2015) U-Net: Convolutional Networks for Biomedical Image Segmentation. Lect Notes Comput Sci (including Subser Lect Notes Artif Intell Lect Notes Bioinformatics) 9351:234–241

Publisher's Note Springer Nature remains neutral with regard to jurisdictional claims in published maps and institutional affiliations.